

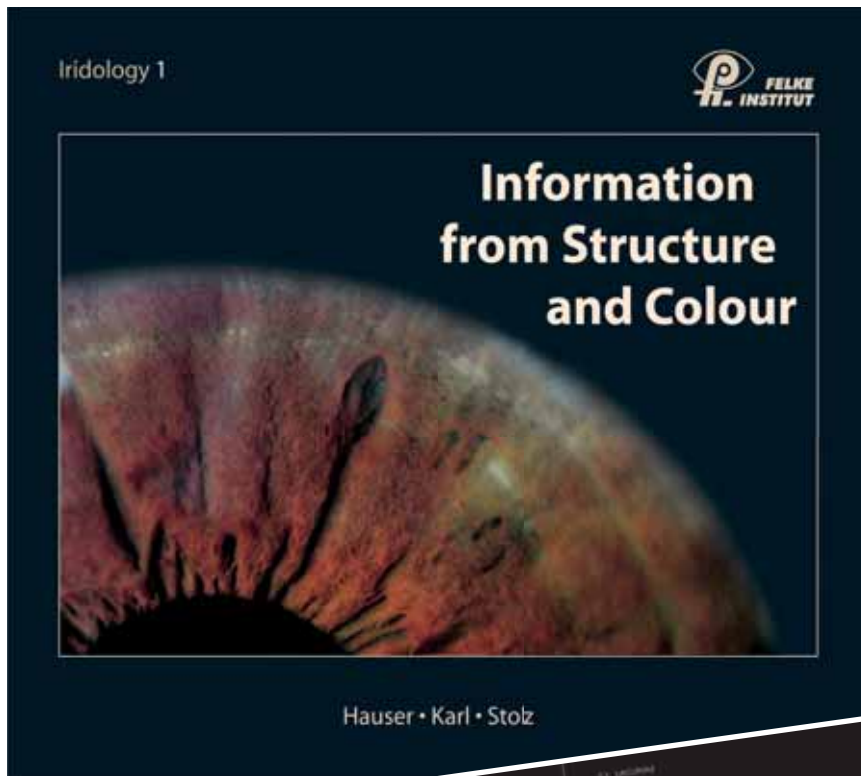
The Standard in Iridology

FELKE INSTITUT

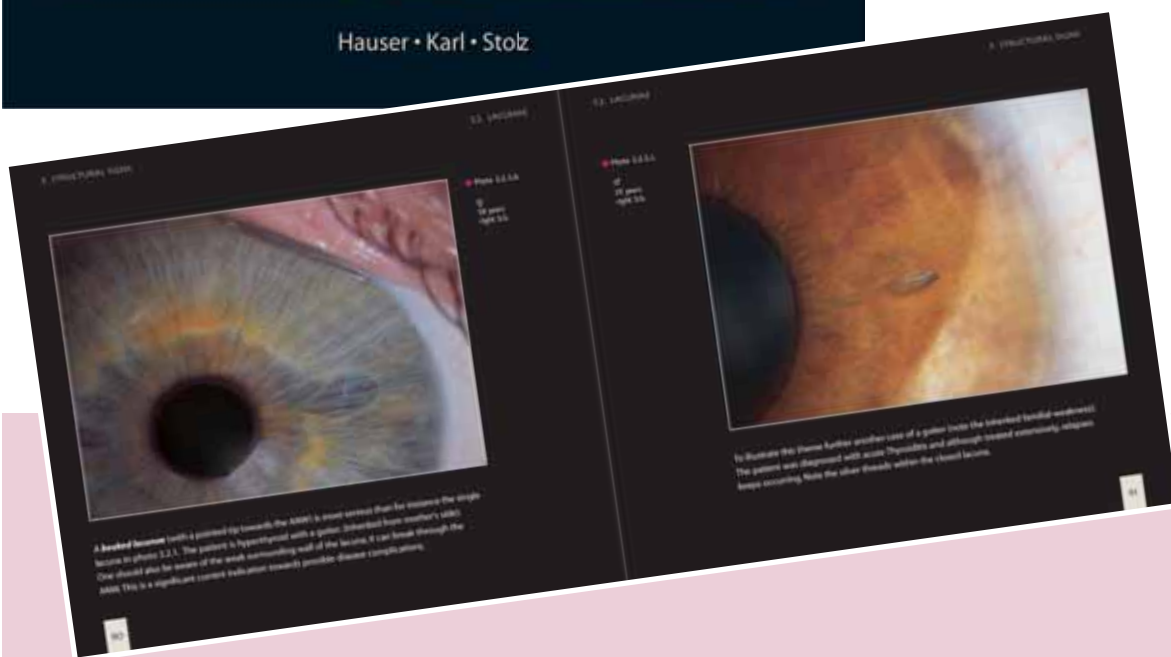Mitschelenstr. 1
DE-70839 Gerlingen

Phone: +49 - (0)7156 - 927744
Fax: +49 - (0)7156 - 4379160

E-mail: info@felke-institut.de
Internet: www.felke-institut.de



After the two much sought-after textbooks *Principles of Iris Diagnosis* and *Differentiation of Iris Markings* by Josef Deck have gone out of print, this new **high-quality textbook** by three foremost students of the late Josef Deck and Josef Angerer is a worthy successor. Willy Hauser, Josef Karl and Rudolf Stolz explain the topics **topography, constitution-disposition-diathesis, structure markings** and **pigments** an **easily** understandable way (based on the new regulations of 1997). The **superb quality** of this unique and **beautiful text- and reference book** is not only enhanced by the more than **30 years of practical experiences** by each of the three authors but also by 180 color illustrations (including approx. **120 excellent iris photos in color**).



Specifications:

260 pages, 10" x 9", high-quality art paper, special sturdy dirt-repelling binding, hard cover, all pages sealed with protective varnish. Printed in Germany.

€ 98,-

Contents

History of Eye Diagnosis, Constitution-Disposition-

Diathesis: What do we mean by constitution? What do we mean by disposition (type - structural)? What do we mean by diathesis (regulatory)? **Constitutions:** Lymphatic constitution. Hematogenic constitution. Mixed constitution. **Dispositions:** Neurogenic type. Weak mesenchyme type. Vegetative-spastic type. Weak glandular type. Tuberculine type. **Diatheses:** Exsudative diathesis (hydrogenoid). Uric acid diathesis. Lipemic diathesis.

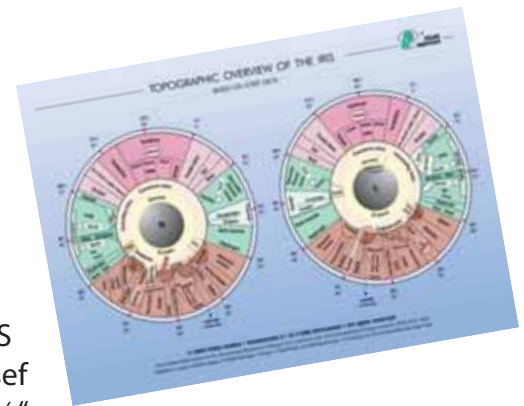
Lacunae: Closed lacuna. Structured leaf-rip lacuna. Closed lacuna brightly bordered with fiber bundles. Open lacuna. Divided lacuna. Asparagus-tip lacuna. Torpedo- and lancet lacuna. Giant lacuna. Ladder- and rung lacuna. **Honeycombs, Crypts, Substance defects. Transversales as genotypes. Neuronic networks. Corkscrew radials.** Weak mesenchyme disposition (connective tissue weakness-iris). Weak glandular disposition (daisy or gland iris). **Spasm rings, spastic furrows and radii solaris, perifocal markings, stages of stroma. Pigments:** Introduction. Criteria of evaluation. Analysis of single pigments. Urorosein pigment. Gastrin pigment. Orange-colored pigments. Hepatotrophic pigments. Basics about pigments. Missing alien pigments. Multitude of hepatotrophic pigments.

Single pigments (solitary pigments). The sectorial heterochromia. Color changes in the ruffle zone. The phenomenon of the accompanying shadow. Bright ruffle zone. Distinct darkened ruffle zone. Complete heterochromia. Different pigmentations. Pigments in the ruffle zone. Topography: Preliminary remarks. Why the term topography? The gastric-intestinal zone. The topography of the intestinal tract. The topography of the pancreas. The topography of the liver and the biliary system. The topography of the urogenital system. The topography of the pulmo-bronchus, pleura, cor and mamma. The nasal sectors. The topography of the thyroid. The topography of the ear and the occiput. The topography of the brain. **Possibilities and limits. Final remarks. Index. Bibliography.**

Order with the book!

The new TOPOGRAPHIC OVERVIEW OF THE IRIS according to Josef Deck. 11 1/2" x 8 1/2"

in four colors, laminated. 4th revised edition 2006. € 10,-



Prepared for envelope with window DIN long

Please send me

Information of Structure and Colour (€ 98,-)

Topographic Overview of the Iris (€ 10,-)

Plus packing and dispatch.

FELKE INSTITUT
POSTFACH 10 05 62
DE-70829 GERLINGEN

Mr. Mrs. Hp. Dr.

Familyname

Firstname

Street

Land, Zip, City

Date

Sign